

PROTECTIVE EFFECTS OF VITAMIN C, VITAMIN E, AND BETA-CAROTENE AGAINST NICOTINE INDUCED OXIDATIVE DAMAGE TO URINARY SYSTEM OF ALBINO RATS

Anwar D Maraqa^{1,*}, Ziad A Shraideh², Ashok K Shakya¹, Rajashri R Naik¹, Zaha A ElAgbar¹, Ghaleb A Oriquat¹

¹Faculty of Pharmacy and Medical Sciences, Al-Ahliyya Amman University, Amman-19328, Jordan

²Department of Biological Science, Faculty of Science, University of Jordan, Amman-11942, Jordan

ABSTRACT

Although the effect of nicotine in tissue damage has been demonstrated in many studies; little is known about the protective effects of vitamin-C, vitamin-E and beta-carotene treatment in the tissue damage that is induced by chronic nicotine exposure. Several studies demonstrate that vitamin C, vitamin E, and beta-carotene treatment prevents tissue damage in various models of inflammation. The aim of this study was to investigate the effects of vitamin-C, vitamin-E, and beta-carotene treatment on nicotine-induced oxidative changes in urinary system in rat, and to explore the possible mechanisms of action. Male Wistar albino rats were injected with nicotine 1.25 mg/kg i.p.) or saline for 28 days. Vitamin-C (125mg/kg b.wt. p.o.), vitamin-E (50mg/kg b.wt. p.o.), and/ or beta-carotene (40mg/kg b.wt. p.o.) were administered on alternative days. At the end of the treatment period kidney and bladder tissue samples were collected and examined histologically. Vitamin C, vitamin E, and beta-carotene supplementation to nicotine-treated animals, reversed partially or completely the cytotoxicity of nicotine in both urinary bladder and kidney tissues. These data suggest that various vitamins(antioxidant) supplementation effectively counteracts the deleterious effect of chronic nicotine administration in urinary system and attenuates oxidative damage possibly by its antioxidant effects.

KEYWORDS:

Nicotine; Vitamins; Oxidative stress, Urinary system

INTRODUCTION

Cigarettes contain more than 4,000 chemicals that have been identified [1]. The gaseous component of mainstream smoke (92% of the total smoke) involves 400-500 different gases which include carbon-monoxide, nitrogen oxide, hydrogen cyanide, formaldehyde and ozone. Particulate matter

of mainstream smoke (8% of the total smoke) contains tar product such as naphthalene, pyrene and nitrosamine [2,3] and metal such as Cadmium, Polonium, Selenium, Mercury, lead and Arsenic [4]. Side stream smoke is a mixture of toxic gases and particles of cancer-causing tar, which represents about 85% of air pollution in closed areas [5]. The nicotine in cigarette activates the sympathetic nervous system with consequent effect on the vasculature, including an increase in heart rate and blood pressure as well as peripheral vasoconstriction [6]. The acute cardiovascular effects of tobacco smoking have been mainly attributed to nicotine and carbon-monoxide [6,7]. The physiological effects of carbon monoxide are ascribed to increase carboxy-hemoglobin level, which acts to reduce the oxygen capacity of blood [6]. Water-Pipe is a traditional method of smoking tobacco leaves in the Middle East and the Indian subcontinent [8]. The most common type of tobacco used in Water-Pipes is called Maassel, which is a sweetened and flavored. Other forms of tobacco may contain less sweeteners/flavors and are called Ajami, Tumbak, or Jurak [9]. Although the effect of nicotine in leading to tissue damage has been demonstrated in many studies [6,7]. Little is known about the protective effects of vitamin-C, vitamin-E and beta-carotene treatment in the tissue damage that is induced by chronic nicotine exposure. The primary purpose of this study was to evaluate the cytotoxicity of nicotine extracted from a Jordanian narghile-tobacco and the possible protective effect of antioxidant (vitamins) on the tissue repair. The use of antioxidants as possible protective agents is justified according to their expected role in detoxification.

MATERIALS AND METHODS

Chemicals. Standard solution of nicotine (1mg/ml in methanol), sodium hydroxide, diethyl ether, methyl tetra-butyl ether and sodium hydroxide were purchased from Sigma-Aldrich Co. (USA). Other chemical were of analytical grades.

Experimental animals. All animals (48 Wistar albino rats) were acclimatized (temperature 25 ± 2 °C; humidity 60%) for 10 days, had free access to water and food. All experiments on animals were conducted as per the Animal Ethics guideline.

Extraction of Nicotine and characterization.

Nicotine was isolated from dried tobacco (Tombak leaves brought locally) with dilute aqueous alkali and ether. Powdered Tombak leaves (100g) were soaked and shaken for 3h with aqueous sodium hydroxide (0.5N, 500 ml). The soaked material was filtered under vacuum through a Buchner funnel using a thin layer of glass-wool and then the leached tombak leaves were washed with water. The dark brown filtrate was transferred to a separatory funnel and extracted with 3x100 ml of ether. The organic layer was collected dried with exsiccated sodium sulfate and decanted into a clean beaker. The collected organic layer was evaporated using a rotatory vacuum evaporated and the oily product was collected [10] and analyzed. In a separate experiment the percent of nicotine in tobacco and percent purity of extracted nicotine was determined using GC-FID following the analytical method described by Stanfill et al. [11]. The tombak contains $3.75 \pm 0.25\%$ of nicotine. The percent purity of extracted nicotine was 97.5%.

Experimental Design. Forty eight male albino rats (6 rats/group) were used in these experiments. The groups were as follows:

Group I: The negative control group received 0.9% NaCl solution intraperitoneally (i.p.)

Group II: The positive control group received nicotine (2 mg/kg/day, i.p. for 28 days)

Group III: treated with nicotine (2 mg/kg/day, i.p., 28 days) + vitamin-E (50 mg/kg/alternative days, b.wt., p.o.)

Group IV: treated with nicotine (2 mg/kg/day, i.p., 28 days) + vitamin-C (125 mg/kg/alternative days, b.wt., p.o.)

Group V: treated with nicotine (2 mg/kg/day, i.p., 28 days) + beta-carotene (50 mg/kg/alternative days, b.wt., p.o.)

Group VI: treated with nicotine (2 mg/kg/day, i.p., 28 days) + vitamin-C (125 mg/kg/alternative days, b.wt., p.o.) + vitamin-E (50 mg/kg/alternative days, b.wt., p.o.)

Group VII: treated with nicotine (2 mg/kg/day, i.p., 28 days) + beta-carotene (50 mg/kg/alternative days, b.wt., p.o.) + vitamin-E (50 mg/kg/alternative days, b.wt., p.o.)

Group VIII: treated with nicotine (2 mg/kg/day, i.p., 28 days) + vitamin-C (125 mg/kg/alternative days, b.wt., p.o.) + beta-carotene (50 mg/kg/alternative days, b.wt., p.o.)

Histological study. To study the effect on histology at the end of the period, kidney and urinary bladder tissues were processed for light microscopy according to Shraideh and Najjar [12]. Rats were sacrificed progressively 6-8 weeks post treatment. The entire organs of animals from each experimental group in addition to control group will be cut out with great care.

RESULTS

Effects on Kidney. Several histological changes in the kidney were observed and are summarized below:

Group- I (Negative control group). Microscopic examination of the kidney revealed the normal structure of kidney cortex, medulla and the collecting ducts and loops of Henle of this group of rats were free from any abnormalities (Figure 1a-c).

Group- II (Positive control group: rats were treated with nicotine). Following histopathological alterations were observed in the kidney tissues of positive control animals. Infiltration of RBCs in the interstitial (intertubular) tissue and edema was observed (Fig. 2a-e).

Figure 2b and 2c shows the disintegration, degeneration of collecting duct and hyaline casts in proximal and distal tubules. Thickening of BM in collecting ducts was also observed (Fig. 2c). Congestion and vacuolization in urothelium, and blood infiltration in kidney calyx was observed in

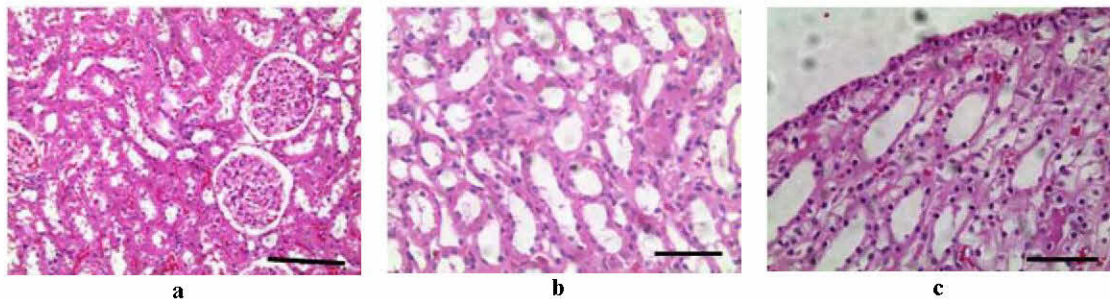


FIGURE 1

Light micrograph of a section in the kidney (Group-1: control), demonstrating (a) normal kidney tissue, (b) collecting ducts and loops of Henle and (c) medulla of kidney (bar= 130 μ m).

Fig. 2d-e.

Group- III (rats exposed to nicotine and treated with vitamin-E). Microscopic examination of kidney tissues of rats exposed to nicotine and treated with vitamin E showed milder histopathological alterations like (a) glomerulus with condensed nuclei, infiltration of RBC between renal

capsules, and disintegration of epithelium of renal tubules (Fig. 3a), (b) Cell exudates in renal tubules and loop of Henle (Fig. 3b), (c) condensed and necrotic nuclei in kidney medulla and urothelium (Fig 3c) and desintegrated epithelium and infiltration of RBC in renal tubules and loop of Henle (Fig. 3d)

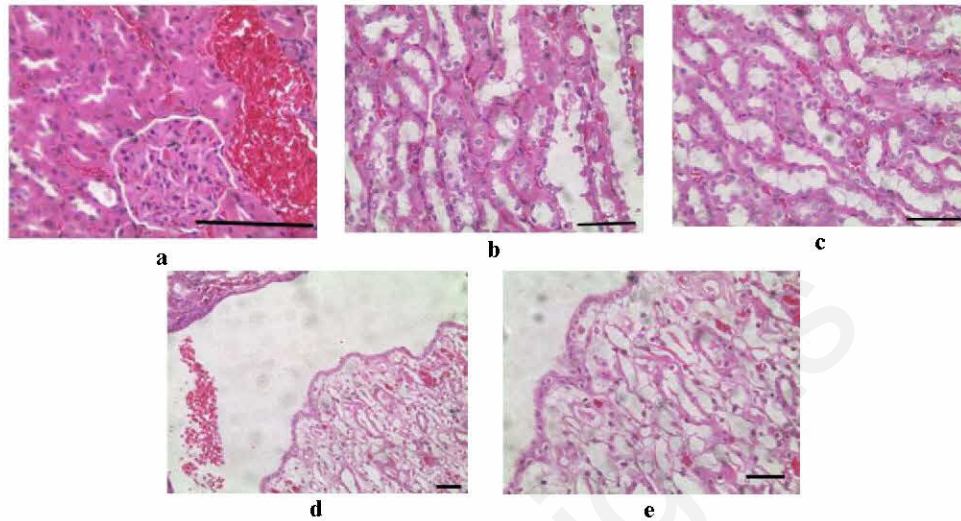


FIGURE 2

Photographs showing sections from kidney of experimental animals of group II indicating (a) bleeding and intertubular infiltration of RBCs, (b) degeneration of tubule and sloughing of epithelia with exudates, (c) irregularity and thickening of basal lamina of collecting ducts (bar= 50 μ m), (d) blood infiltration and (e) congestion of urothelium.

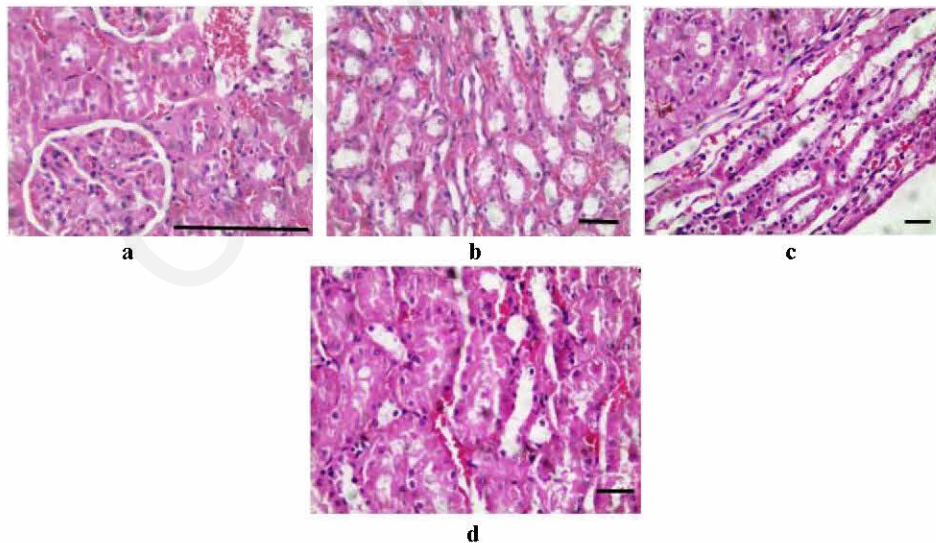


FIGURE 3

Photographs showing sections from kidney of experimental animals of group III indicating (a) condensation of glomerulus and infiltration of RBCs, between renal capsule and renal tubules with disintegration of renal tubules, (b) exudates in renal tubules and loop of Henle, (c) disintegration of epithelium of collecting ducts, (d) disintegration epithelium of renal tubules and loops of Henle with blood infiltration (bar= 50 μ m).

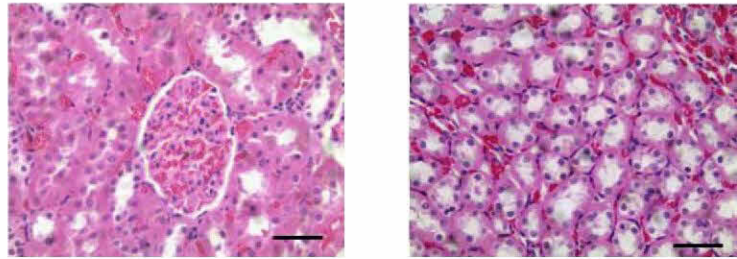


FIGURE 4

Photographs showing sections from kidney of experimental animals of group IV: (a) normal appearance of glomerulus and well preserve renal tubules and (b) normal structure of Loops of Henle and collecting ducts. (bar= 65 μ m).

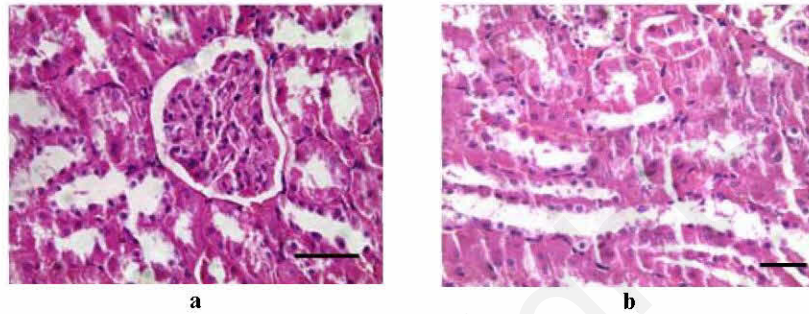


FIGURE 5

Photographs showing sections from kidney of experimental animals of group V: (a) condensed glomerulus and slight disintegration of renal tubule epithelium with blood infiltration between tubule and (b) condensed nuclei in epithelium of collecting tubules and loops of Henle (bar= 50 μ m).

Group IV (rats exposed to nicotine and treated with vitamin C). Microscopic examination of kidney tissues of rats exposed to nicotine and treated with vitamin C showed well preserved tissues, when compared with the control. (Fig. 4a-b).

Group V (rats exposed to nicotine and treated with beta-carotene). Microscopic examination of kidney tissues of rats exposed to nicotine and treated with beta-carotene, showed milder histopathological alterations viz. (a) Glomeruli are condensed, with slight disintegration of lining epithelium and blood infiltration between renal tubules.(Fig. 5a) and (b) collecting tubules,

loop of Henle and urothelium showed condensed nuclei (Fig. 5b).

Group VI (rats exposed to nicotine, treated with vitamin C and E). On Microscopic examination of kidney tissues of rats exposed to a mixture of nicotine and vitamin C, showed well preserved tissues, when compared with the control. The cross sectional view showed well protected cells (Fig. 6a), normal nephrons showing minor disintegration of tubular epithelium (Fig. 6b) and well protected collecting tubules and loops of Henle (Fig. 6c).

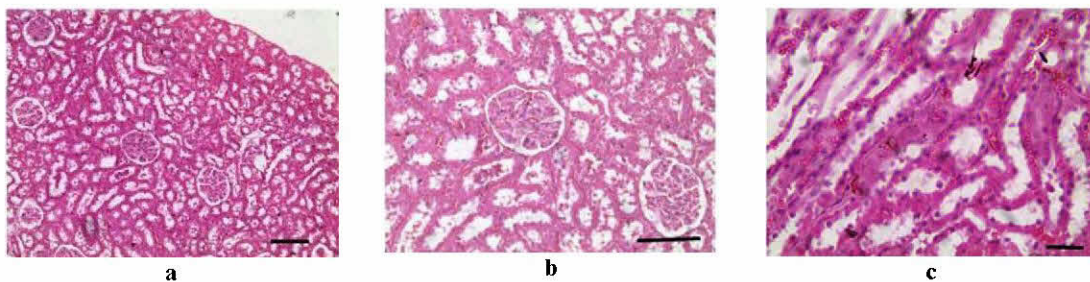


FIGURE 6

Photographs showing sections from kidney of experimental animals of group VI: (a) normal renal corpuscles and renal tubules, (b) corpucles and renal tubules, epithelium of tubules shows some disintegration and exudates (bar= 65 μ m). and (c) normal collecting tubule and loops of Henle (bar= 50 μ m).

Group VII (rats exposed to nicotine and treated with vitamin E and beta-carotene). Microscopic examination of kidney tissues of rats exposed nicotine and treated with β -carotene and vitamin E showed well preserved tissues, when compared with the control. Overview of kidney cortex shows well preserved tissues (Fig. 7a). Glomeruli showed slight condensation of nuclei and slight disruption of renal tubules epithelial lining (Fig. 7b). Loops of Henle (Fig. 7c), Urothelium and kidney pelvis are well protected (Fig. 7d).

Group VIII (rats exposed to nicotine and treated with vitamin C and beta-carotene). Microscopic examination of cross sectional view of kidney tissues showed well preserved tissues. Renal capsule and renal tubules are well protected (Fig. 8a). Collecting tubules, loops of Henle and urothelium showed normal structure.(Fig. 8b-c)

Effect on Urinary bladder. Control rats. Microscopic examination of the urinary bladder of control group revealed normal structure, with intact

transitional epithelium. (Fig. 9).

Group II (rats exposed to nicotine). Histopathological alterations were observed in the sectional view of urinary bladder *viz.* (a) Transitional epithelium with condensed nuclei indicating necrosis or disintegration. In addition to inflammatory areas in submucosa. (Fig. 10a), necrotic and inflammatory areas in muscle layers (Fig. 10b).

Group III (rats exposed to nicotine and treated with vitamin E). Microscopic examination of urinary bladder tissues of rats exposed to nicotine and treated with vitamin E, showed milder histopathological alterations.

Group IV (rats exposed to nicotine and treated with vitamin C). shows well preserved tissues, when compared with the control.

Group V (rats exposed to nicotine and treated with beta-carotene). Microscopic examination of urinary bladder tissues of rats exposed to a mixture of nicotine and beta-carotene, showed milder histopathological alterations.

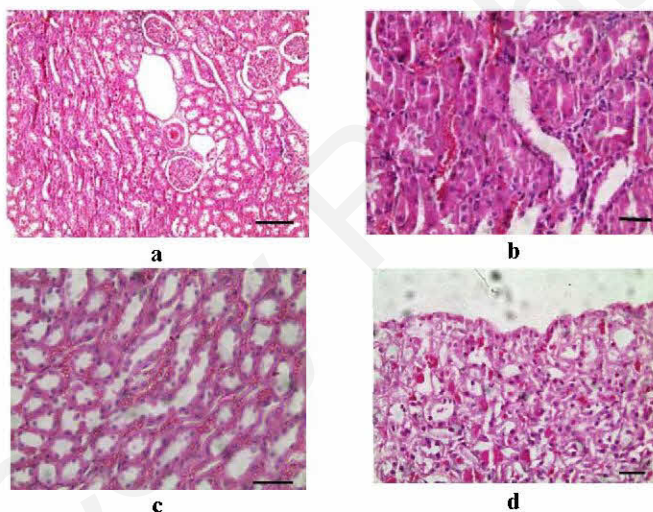


FIGURE 7

Photographs showing sections from kidney of experimental animals of group VII: (a) renal structures relatively are preserved with some degenerative changes; (b) renal tubules with condensed nuclei (bar= 65 μ m); (c) normal collecting tubule and loops of Henle (bar= 50 μ m) and (d) collecting ducts with normal urothelium.

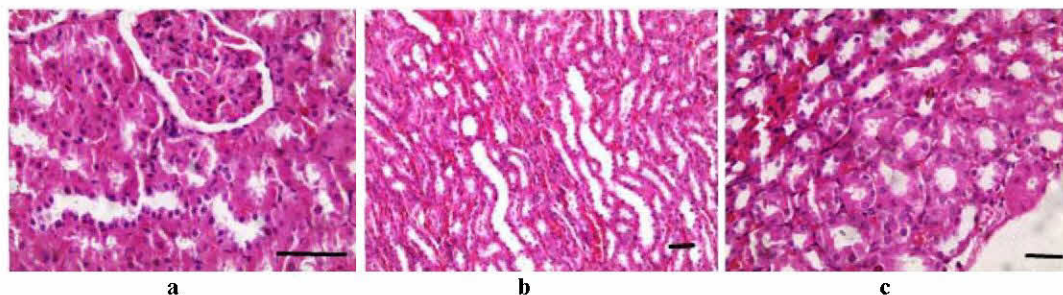


FIGURE 8

Photographs showing sections from kidney of experimental animals of group VIII: (a) renal corpuscle and renal tubule; (b) renal tubules (bar= 50 μ m), and (c) well preserved collecting ducts and loops of Henle (bar= 65 μ m).

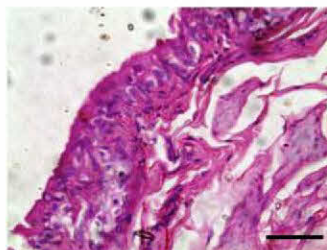

FIGURE 9

A section from urinary bladder of Group I (control), showing normal transitional epithelium (bar= 50 μ m).

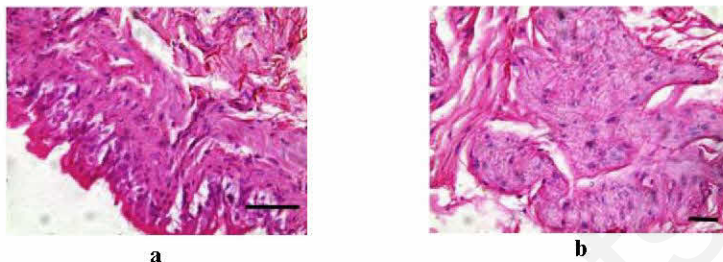


FIGURE 10

Photographs showing sections from urinary bladder of experimental animals of group II: (a) Transitional epithelium with loss of normal contour and spaces between epithelial cells and (b) muscularis layer of urinary bladder showing loss of organization and degenerative changes in smooth muscles (bar= 50 μ m).

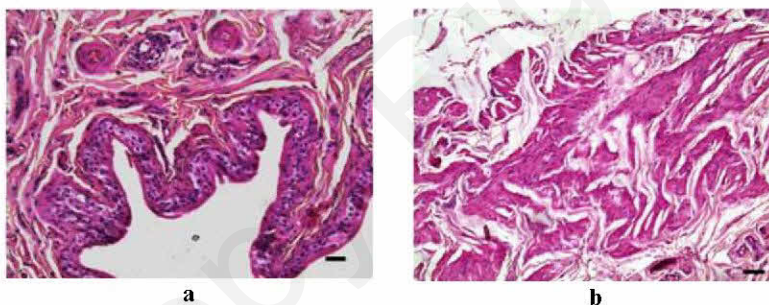


FIGURE 11

Photographs showing sections from urinary bladder of experimental animals of group III, (a) showing normal appearance of transitional epithelium and (b) normal bundle of smooth muscle cells (bar= 50 μ m).

Group VI (rats exposed to nicotine, treated with vitamin C and E). Microscopic examination of urinary bladder tissues of rats exposed to nicotine and treated with vitamin C and vitamin E showed well preserved tissues. Transitional epithelium showed good appearance and no nuclear condensation was observed. Inner smooth muscles have normal structure.

Group VII (rats exposed to nicotine, treated with vitamin E and beta-carotene). Microscopic examination of urinary bladder tissues of rats exposed to nicotine and a mixture of carotene and vitamin E showed well preserved tissues, when compared with the control. Transitional epithelium is well preserved (Fig. 11a). Smooth muscles have normal structure (Fig. 11b).

Group VIII (rats exposed to nicotine, treated with vitamin C and beta-carotene). Microscopic

examination of urinary bladder tissues of rats exposed to nicotine and treated with β -carotene and vitamin C showed well preserved tissues, when compared with the control. Transitional epithelium and inner smooth muscle layer are well preserved and have normal structure (Fig. 12a). Smooth muscle layer (middle) is well preserved (star), with few necrotic nuclei (Fig. 12b). Outer smooth muscle layer and adventitia are less affected, and showed normal structure (Fig. 12c).

DISCUSSION

This work concentrated on the cytotoxicity of nicotine extracted from a Jordanian narghile-tobacco. The effect of nicotine on histology of selected tissues of kidney and urinary bladder of

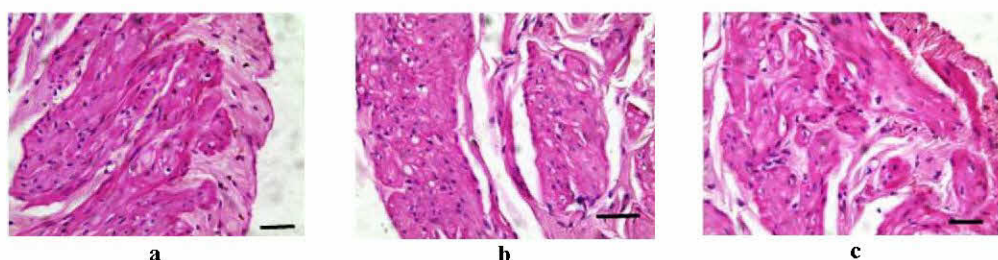


FIGURE 12

Photographs showing sections from urinary bladder of experimental animals of group VIII: (a) normal transitional epithelium and smooth muscle bundles, (b) normal arrangement of smooth muscles layer with few pyknotic nuclei and (c) normal smooth muscle layers and adventitia (bar= 50 μ m).

albino rats, and the possible protective effect of antioxidants (vitamin-C, vitamin-E, and β -carotene) were investigated.

Nicotine administration (1.25 mg/kg i.p) caused drastic histological damage to the kidneys of treated rats. These changes included: edema or infiltration of RBCs in the interstitial (intertubular) tissues, degenerated kidney tubules and sloughing oxidants in tubular lumen; degeneration of collecting ducts, congestion, vacuolization in urothelium and blood infiltration in kidney calyx. These results are consistent with previous studies on renal damage caused by chronic nicotine administration [13]. In that mentioned study, Melatonin were used to reverse urinary and aorta damage in the rat due to chronic nicotine administration [13]. In this study Antioxidant were investigated for their protective role. Combine administration of nicotine with vitamin-C, vitamin-E, beta-carotene, or their combinations resulted in marked ameliorations of the renal changes using histological observations.

Administration of vitamin-E combined with nicotine caused a minimum protection to renal tissues. Microscopic examination of kidney tissues of rats exposed to a mixture of nicotine and vitamin-E, showed milder histopathological alterations. Kidney and urinary bladder are still affected by nicotine treatment. Microscopic examination of kidney tissues of rats exposed to a mixture of nicotine and vitamin-C showed well preserved tissues, when compared with the control. Kidney and urinary bladder tissues look nearly similar to control.

Kidney of rats exposed to nicotine and treated with beta-carotene showed milder histopathological alterations. Glomeruli were condensed, with slight disintegration of lining epithelium, and blood infiltration between renal tubules. Microscopic examination showed a good protection of collecting tubules and loops of Henle.

Administration of vitamin-C and Vitamin-E together showed well preserved tissues, when compared with the control. There was only a slight disintegration of tubular epithelium.

The kidneys of rats treated with nicotine, followed by vitamin-E and beta-carotene administration, preserved these tissues from possible damage, when compared with the control. Kidney

cortex shows well preserved tissues, glomeruli with slight condensation of nuclei and slight disruption of epithelial lining of renal tubules. The loop of Henle was well protected.

The best protection of kidney and urinary bladder against nicotine treatment was achieved by administration of vitamin-C and beta-carotene together. Microscopic examination of kidney tissues of rats exposed to nicotine and a mixture of beta-carotene and vitamin-C showed well preserved tissues, when compared with the control. Renal capsule and renal tubules are well protected. Collecting tubules, loops of Henle and urothelium showed normal structure. Urinary bladder showed well preserved transitional epithelium. In addition, inner smooth muscle layer are well preserved and have normal structure. Gawish et al. [14] obtained similar protective effects of green tea extraction some organs of Swiss albino mice by using histological, histomorphometrical and cytogenetical studies.

The ameliorative effect of vitamins against nicotine can be explained by their antioxidant activity. In conclusions, the administration of vitamins might suppress the cytotoxicity of nicotine. This study suggested that vitamin combination may be useful in combating tissue damage caused by nicotine toxicity.

ACKNOWLEDGEMENT

This project has been supported from the Dean of Research- Al-Ahliyya Amman University (grant No.3/13/2011-12). The authors would like to thank Prof. Dr. Mahmood Hamash for his suggestions and for reviewing the manuscript.

REFERENCES

- [1] Hecht, S.S.(2012) Research opportunities related to establishing standards for tobacco products under the Family Smoking Prevention and Tobacco Control Act. Nicotine Tobacco Research, 14(1):18-28.

- [2] Kaiserman, M.J. and Jickert, W. (1992) Carcinogens in Tobacco Smoke: Benzo {a} Pyrene from Canadian Cigarette and Cigarette Tobacco. *American Journal of Public Health*, 82(7): 1023-10.
- [3] Yarnell, G.J. (1996) Smoking and Cardiovascular Disease. *Quarterly Journal of Medicine*, 89: 493-498.
- [4] Chiba, M. and Masironi, R. (1992) Toxic and Trace Element in Tobacco and Tobacco Smoke. *World Health Organization*, 70(2): 269-275.
- [5] Lesmes, R.G. and Donofrio, K.H. (1992) Passive Smoking: The Medical and Economic Issue. *American Journal of Medicine*, 93(Suppl 1A): 38S-42S.
- [6] Higman, D.J. and Powell, J.T. (1994) Smoking and Vascular Reactivity. *Journal of Smoking-related disorders*, 5(3): 157-162.
- [7] Thomas, D. (1993) Tobacco Smoking and Cardiovascular Disease. *Rev. Prat.*, 43(10): 1218-1222.
- [8] Al-Mutairi, S.S., Shihab-Eldeen, A.A., Mojiminiyi, O.A. and Anwar, A.A. (2006) Comparative Analysis of the Effects of Hubble-Bubble (Sheesha) and Cigarette Smoking on Respiratory and Metabolic Parameters in Hubble-Bubble and Cigarette Smokers. *Respirology*, 11: 449-455.
- [9] Maziak, W., Ward, K.D., Afifi Soweid, R.A. and Eissenberg, T. (2004) Tobacco Smoking Using a Waterpipe: a Re-emerging Strain in a Global Epidemic. *Tobacco Control*, 13: 327-333.
- [10] Elagbar, Z. (2004) A Practical Handbook for Organic and Pharmaceutical Organic Chemistry. Al-Ahliyya Amman University, Amman, Jordan.
- [11] Stanfill, S.B., Jia, L.T., Ashley, D.L. and Watson, C.H. (2009) *Journal of Chromatographic Science*, 47: 902-909.
- [12] Shraideh, Z.A. and Najjar, H. (2011) Histological changes in tissues of trachea and lung alveoli of albino rats exposed to the smoke of two types of narghile tobacco products. *Jordan Journal of Biological Sciences*, 4(4): 149-156.
- [13] Sener, G., Kapucu, C., Paskaloglu, K., Ayanoglu-Dülger, G., Arbak, S., Ersoy, Y. and Alican I. (2004) Melatonin reverses urinary system and aorta damage in the rat due to chronic nicotine administration *Journal of Pharmacy and Pharmacology*, 56(3): 359-66.
- [14] Gawish, A., Ramadan, S., Hassan, A. and Issa, A. (2010) Morphometrical, histopathological, and cytogenetical ameliorating effects of green tea extract on nicotine toxicity of the testis of rats. *Journal of Cytology and Histology*, 1(2): 105-111.

Received: 05.03.2016

Accepted: 30.09.2016

CORRESPONDING AUTHOR

Anwar D Maraqa

Faculty of Pharmacy and Medical Sciences, Al-Ahliyya Amman University, Amman-19328, Jordan

Email: nwr_maraqa88@yahoo.com